

УДК 619:616.995.121.56

DOI: 10.31016/1998-8435-2018-12-3-33-41

# Hydatidosis of Camels and Sheep Slaughtered in Aswan Governorate, Southern Egypt

Ahmed K. Dyab<sup>1\*</sup>, Mohammed E. Marghany<sup>1</sup>, Ragaa A. Othman<sup>1</sup>,  
Mahmoud A. Ahmed<sup>2</sup>, Osama H. Abd-Ella<sup>3</sup>

<sup>1</sup> Department of Medical Parasitology, Faculty of Medicine, Assiut University

<sup>2</sup> Department of Parasitology, Faculty of Veterinary Medicine, Aswan University

<sup>3</sup> Department of Medical Parasitology, Faculty of Medicine, South Valley University

\* Corresponding Author: Prof. Dr. Ahmed Dyab: ahmedsaf2001@yahoo.com, Ahmed2015@aun.edu.eg

Present address: Head of Parasitology Department, Faculty of Medicine, Assiut University, Egypt, 71515

Received on: 27.02.2018; accepted for printing on: 25.09.2018

## Abstract

**Background:** Hydatidosis is an infection caused by the cystic larval stage of *Echinococcus granulosus*. This disease is a zoonotic disease has a worldwide distribution and common in developing and undeveloped countries.

**Objectives:** The objective of the present study is to studying the infection rate and predilection seats of hydatid cyst affections among slaughtered food animals in Aswan Governorate, southern Egypt and study the effect of age and sex of infected slaughtered animals on the infection with hydatid cyst. Also, study the effect of seasonal variations in the infection with hydatid cyst among slaughtered animals. In addition, the macroscopic examination, microscopic examination, scanning electron microscopy and histopathological studies for the collected hydatid cyst are examined.

**Methods:** This investigation was carried out from August 2015 to July 2016 in two main slaughterhouses in Aswan Governorate to study the hydatidosis in camels and sheep. By routine meat inspection, hydatid cyst count and characterization was conducted.

**Findings:** A total of 2080 camels and 674 sheep were examined. Of these, 173 (8.32%) camels and 3 (0.45%) sheep were found to harbour one or more hydatid cysts. Female and older age slaughtered animals were more susceptible to infection with these metacestode than males and younger animals. Hydatid cyst infection in slaughtered animals is most commonly found in lung followed by liver while mixed infection in both lung and liver was found only in camel. Hydatid cyst in slaughtered camels was higher in autumn followed by winter, while hydatid cyst in slaughtered sheep was found only in autumn season. Fertile cysts in lung and liver of slaughtered camels was 83.4% and 30% respectively. While the fertility of hydatid cyst in infected lung and liver of sheep was 100%.

**Main conclusions:** This study reported that slaughtered animals were infected with relatively high infection rate of hydatid cyst may be due to the presence of socio-economic conditions favourable for the disease and maintenance of high level of infection. So must design governmental control programs against hydatidosis to minimize the infection rate in Aswan Governorate and ensure effective protection not only for animal population but also for humans at risk of contracting the infection.

**Keywords:** hydatid cyst, camel, sheep, Aswan, Egypt, zoonosis.

**For citation:** Dyab A. K., Marghany M. E., Othman R. A., Ahmed M. A., Abd-Ella O. H. Hydatidosis of Camels and Sheep Slaughtered in Aswan Governorate, Southern Egypt. *Rossiyskiy parazitologicheskii zhurnal = Russian Journal of Parasitology*. 2018; 12(3):33–41.

DOI: 10.31016/1998-8435-2018-12-3-33-41

© Ahmed K. Dyab, Mohammed E. Marghany, Ragaa A. Othman, Mahmoud A. Ahmed, Osama H. Abd-Ella

# Эхинококкоз верблюдов и овец, убитых в административном округе Асуан, южной части Египта

Ахмед К. Дьяб<sup>1\*</sup>, Мохаммед Е. Маргани<sup>1</sup>, Рагаа А. Отман<sup>1</sup>,  
Махмуд А. Ахмед<sup>2</sup>, Осама Х. Абд-Элла<sup>3</sup>

<sup>1</sup> Департамент медицинской паразитологии, Медицинский факультет Асьютского университета

<sup>2</sup> Департамент паразитологии, Ветеринарный факультет Асуанского университета

<sup>3</sup> Департамент медицинской паразитологии, Медицинский факультет Университета Южной долины

\* Автор для корреспонденции: профессор д-р Ахмед Дьяб: ahmedsaf2001@yahoo.com, Ahmed2015@aun.edu.eg

Действующий адрес: Глава Департамента паразитологии, Медицинский факультет Асьютского университета, Египет, 71515.

Поступила в редакцию: 27.02.2018; принята в печать: 25.09.2018

## Аннотация

**Исходная информация:** Эхинококкоз является инфекцией, вызванной личиночной стадией *Echinococcus granulosus*. Данное заболевание является зоонозом, распространенным во всем мире и характерен для развитых и слаборазвитых стран.

**Цели:** Целью данного исследования является изучение зараженности эхинококками и предрасположенности мест повреждения гидатидой среди убитых животных в административном округе Асуан, южной части Египта, и изучение влияния возраста, пола животных и сезона года на заболеваемость эхинококками. Проведены макроскопическое и гистологическое исследования, растровая электронная микроскопия и гистопатологические исследования обнаруженных при вскрытии убитых животных гидатид.

**Методы:** Данное лабораторное обследование проводили с августа 2015 года по июль 2016 года в двух основных скотобойнях административного округа Асуан для изучения эхинококкоза у верблюдов и овец.

**Выводы:** Всего исследовали 2080 верблюдов и 674 овец. Среди них у 173 верблюдов (8,32%) и у 3 овец (0,45%) были обнаружены переносчики одной или нескольких гидатид. Убитые животные женского пола и старшего возраста были более подвержены заражению данным плероцеркоидом, чем животные мужского пола и более молодого возраста. Гидатиды у убитых животных чаще всего обнаруживали в легком, менее часто - в печени, в то время как множественное заражение и в легком и в печени обнаруживали только у верблюдов. Более высокая встречаемость гидатид у убитых верблюдов была осенью, реже - зимой, в то время как гидатиды у убитых овец были обнаружены только в осенний период. Фертильные кисты в легких и печени убитых верблюдов составляли 83,4% и 30% соответственно, в то время как фертильные кисты в зараженных легких и печени овец составляли 100%.

**Основные выводы:** Данное исследование показало, что убитые животные были заражены гидатидами в высокой возможно из-за существующих социально-экономических условий, благоприятных для развития заболевания и сохранения высокого уровня зараженности. Таким образом, обязательным является создание государственных программ контроля эхинококкоза для снижения уровня распространенности в административном округе Асуан и обеспечения эффективной защиты не только животных, но и людей от риска контактирования с инвазией.

**Ключевые слова:** гидатида, верблюд, овца, Асуан, Египет, зооноз.

**Для цитирования:** Дьяб А. К., Маргани М. Е., Отман Р. А., Ахмед М. А., Абд-Элла О. Х. Эхинококкоз у верблюдов и овец, убитых в административном округе Асуан, южной части Египта // Российский паразитологический журнал. 2018. Т. 12. № 3. С. 33–41.

DOI: 10.31016/1998-8435-2018-12-3-33-41

## Introduction

Hydatidosis is a zoonotic disease caused by the hydatid cysts which is larval stage of the *Echinococcus granulosus* tapeworm. The hydatid cyst is diagnosed when animals are slaughtered in abattoirs and detected in the different parts of the carcass. This disease has a worldwide distribution and common in developing and undeveloped countries, including the Mediterranean region, Yang et al. (2005).

Hydatid cyst is a fluid-filled, spherical, unilocular cyst that consists of an inner germinal layer of cells supported by a characteristic acidophilic-staining, acellular, laminated membrane of variable thickness containing numerous tiny protoscolexes. Hydatid cyst most often develop in the liver and lungs and also develop in the kidneys, spleen, nervous tissue, bone and other organs, Seimenis (2003).

Camels and sheep slaughtered animals have indicated high rates of infection leading to a nega-

tive economic impact and losses in yield in internal organs and other products like milk and meat, Lahmar et al. (2007).

This study was prepared due to lack of available studies on hydatid cyst of slaughtered animals in Aswan Governorate, provide a scientific perception of the prevalence of such parasitic disease that affect negatively on the productivity of animals, work to identify them and prepare recommendations to resist the spread of these metacestodes

## Materials and Methods

### Description of the Study Area

The study and determination of hydatidosis was conducted from August 2015 to the end of July in 2016 in Aswan Governorate, southern Egypt in two slaughterhouses (Aswan in Aswan city, and Draw in Draw city).

### Examination of Slaughtered animals

A total of slaughtered animals comprising 2080 camels and 674 sheep were examined for

detection of hydatid cyst from different ages, sex, seasonal variation and in different organs.

### Examination of Unilocular Hydatid Cysts

The hydatid cysts were identified in the slaughtered animals and were examined grossly, microscopically and by scanning microscopy. Generally, all of the cysts were recovered from the livers and lungs.

### Determination of the Fertility of Hydatid Cysts

Hydatid cyst was washed several times in sterile PBS, pH 7.2. Cyst surfaces were sterilized by 70% ethyl alcohol and their fertility was determined by the presence of free protoscolexes in cystic fluid by microscopic examination of a wet mount drop. Hydatid fluid with protoscolexes was collected as described by Smyth (1967).

### Data analysis

Statistical analysis was done by using SPSS (Statistical Package for Social Science) program.

## Results

Table 1

Hydatid Cyst Infection Rates in slaughtered animals

Metacestode	Animal species	Inspected/ Infected (%)	Aswan	Draw	Total	X <sup>2</sup>	P-value
<i>Hydatid cyst</i>	Camels	Inspected	662	1418	2080	0.021	0.884
		Infected (%)	56 (8.5%)	117 (8.25%)	173 (8.32%)		
	Sheep	Inspected	669	5	674	1	0.317
		Infected (%)	3 (0.45%)	0	3 (0.45%)		

Table 2

Distribution of Hydatid Cysts According to Sex

Metacestode	Animal species	Inspected/ Infected (%)	Male	Female	Total	X <sup>2</sup>	P-value
<i>Hydatid cyst</i>	Camel	Inspected	1987	93	2080	78.1	<0.0001
		Infected (%)	112 (5.63%)	61 (65.6%)	173 (8.32%)		
	Sheep	Inspected	446	228	674	1	0.316
		Infected (%)	1 (0.2%)	2 (0.9%)	3 (0.44%)		

Table 3

Distribution of Hydatid Cysts According to Age

Metacestode	Animal species	Inspected/Infected (%)	Young (<2 years old)	Adult (>2 years old)	Total	X <sup>2</sup>	P-value
<i>Hydatid cyst</i>	Camels	Inspected	2000	80	2080	67.9	<0.0001
		Infected (%)	124 (6.2%)	49 (61.25%)	173 (8.32%)		
	Sheep	Inspected	429	245	674	1	0.316
		Infected (%)	1 (0.23%)	2 (0.8%)	3 (0.44%)		

Table 4

Infection Rates of Hydatid cysts in different organs

Animal species	Total inspected	Total infected	Lung		Liver		Lung & Liver		X <sup>2</sup>	P-value
			Infected	%	Infected	%	Infected	%		
Camel	2080	173	160	92.5	7	4.03	6	3.47	236.4	<0.0001
Sheep	674	3	1	33.33	2	66.67	0	0	101	<0.0001

Table 5

Distribution of Hydatid Cysts According to season

Metacestode	Animal Species	Inspected/Infected (%)	Spring	Summer	Autumn	Winter	Total	X <sup>2</sup>	P-value
<i>Hydatid cyst</i>	Camels	Inspected	611	446	443	580	2080	2.2	0.529
		Infected (%)	33 (5.4%)	38 (8.5%)	46 (10.4%)	56 (9.6%)	173 (8.32%)		
	Sheep	Inspected	197	180	88	209	674	9.1	0.023
		Infected (%)	0	0	3 (3.41%)	0	3 (0.44%)		

Table 6

The fertility of Hydatid cyst which was collected from slaughtered animals

Animal species	Infected organ	Frequency of cysts	Fertile cyst	% of fertile cyst	Infertile cyst	% of infertile cyst
Camel	Lung	163	136	83.4	27	16.6
	liver	10	3	30	7	70
Sheep	Lung	1	1	100	0	0
	Liver	2	2	100	0	0

### Gross examination

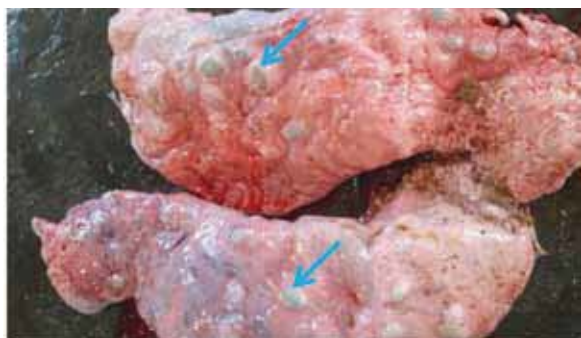

Figure (1): Lung of camel with heavy infection of hydatid cyst showing a presence of multiple cysts (arrows) with water under pressure in the pulmonary parenchyma with different size in two lobes of the lung (X5, Bar = 4cm)

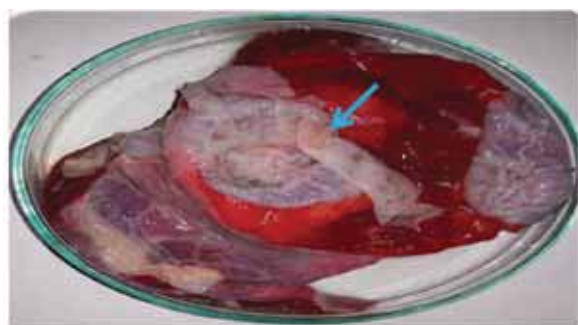


Figure (2): Hydatid cyst inside lung tissue of camel showing its internal whitish germinal layer (arrow) after evacuated in a petri dish. On incision, the protoscolexes in hydatid fluid brood capsules were attached to the inner surface of the cyst wall (X5)

### Histopathological and fertility examination of Hydatid cyst

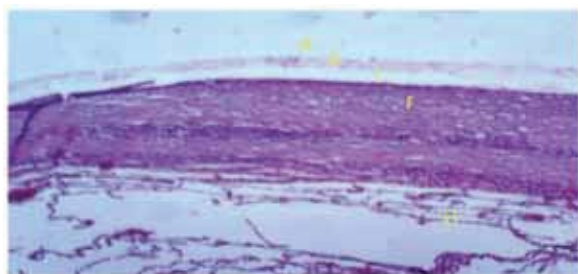


Figure (3): Histological section of hydatid cyst inside lung tissue of naturally infected camel stained with H&E (x 10)

Showing that it was composed of an inner germinal layer, a laminated layer produced by the germinal cells (P: Protoscolexes, G: germinal layer, L: laminated layer, LT: lung tissue and F: Fibrous capsule).




Figure (4): Fertile hydatid cyst show unstained hydatid sand by wet mount drop showing protoscolexes and noted several rostellum hooks present on it clearly visible in a circular manner appear as rays (x 40)

### Scanning electron microscopy on Hydatid cyst

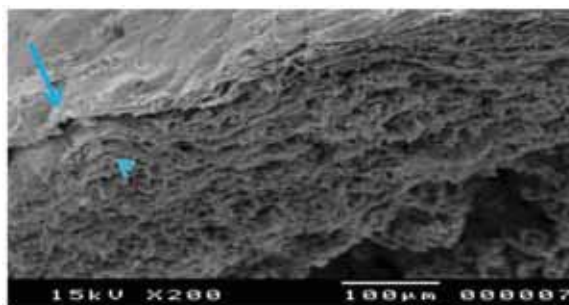


Figure (5): Higher magnification hydatid cyst wall from lung tissue of camel showing visualization of (arrow) indicates the inner germinal layer while (head arrow) indicates outer laminated layer (15 KV x 200, scale 100 μm)




Figure (6): Scanning electron microscope on hydatid cyst of the lung from camel, showing Large swellings without projections indicated the development of brood capsules from the germinal layer (15 KV x 350, scale 50 μm)

## Discussion

### The infection rate of Hydatid cyst in slaughtered camels and sheep

#### Hydatid cyst in slaughtered camels

Camel hydatidosis recorded in this study (8.32%) was very close to the previous reports of Kasem (2013) (7.17%), Dyab et al. (2005), Khalifa et al. (2005), Abo El-Ala (2014), Hassanin et al. (2013) in Egypt, Al-Salami et al. (2009) in Yemen, Magaji et al. (2011) in Nigeria, Lahmar et al. (2004) in Tunisia, Toulah et al. (2012) in Saudi Arabia. On the contrary, the comparatively lower infection rate of camel hydatidosis has been reported by Haridy et al. (2006) (2.53%) in Egypt, Kassem and Gdoura (2006) in Libya. Other reports elsewhere in the world reported relatively higher infection rate in camel Mohammed and El-Malik (2000) (79.5%) in Sudan, Bardonnnet et al. (2003) in Algeria, Rokni (2009), Fathi et al. (2012) in Iran, Salem et al. (2011) in Mauritania, Salih et al. (2011) in Ethiopia. While Muqbil et al. (2012) in Yemen not recorded camel's infection with hydatid cyst in their survey.

In this study the camel possesses the highest infection rate with hydatid cyst this may be due to the owner of the camel has a dog which is the definitive host of *Echinococcus granulosus*. This may help in spreading the disease. In these communities dogs have an access to the infected offal. This situation was previously described by Mohamed and Magzoub (1989). There was very highly statistically significant in camel infected with hydatid cyst in associated with different metacestodes infection ( $P < 0.0001$ ). There was no significant differences of hydatid cyst infection in camels in different slaughterhouses ( $P > 0.05$ ).

#### Hydatid cyst in slaughtered sheep

This study revealed that the infection rate of hydatid cyst among slaughtered sheep was (0.45%) and this agreed with result reported by Haridey et al. (2006) (0.3%), Abo El-Ala (2014) (0.96%) in Egypt, Haridy et al. (2000) (0.33%), Ibrahim et al. (2011), Osman (2013) in Sudan, Muqbil et al. (2012) in Yemen, Kadir and Rasheed (2008) in Iraq. While such result was higher than the result reported by Pendnekar et al. (2009) (0.075%) in India. While such result was lower than result obtained by Haridy et al. (2000) in Egypt, Saeed et al. (2000) in Iraq, El-Mahdi et al. (2004) in Sudan, Ahmed et al. (2006) in Pakistan, Asma (2009) in India, El-Ibrahim (2009) in Palestine, Rokni

(2009) in Iran, Ibrahim (2010) in Saudi Arabia, Hamrat et al. (2011) in Algeria, Salem et al. (2011) in Mauritania, Fikire et al. (2012) in Ethiopia.

This study revealed very low infectivity with hydatid cyst in sheep this may be explained by the fact that those animals were slaughtered in early age. Interestingly, reports published by Hassanin et al. (2013) showed a higher infection rate in these species. This, however, might possibly be attributed to the health and aged factor of the animals. The difference in hydatidosis infection rate between countries for infected camel and sheep could be associated with different factors like control measures put in place, the level of community awareness about the disease, education and economic status of the population, the farming community, variation in the temperature, environmental conditions, the nature of the pasture and the way of raising of these animals, levels of exposure and the maturity and viability of eggs Bardonnnet et al. (2003).

### The infection rate of Hydatid cyst in slaughtered camels and sheep in relation to sex

In this study, females of slaughtered camels and sheep were more susceptible for Hydatid cyst (65.6%) and (1.07%) than males (5.63%) and (0.2%) respectively. This result agreed with Abdel-Hafez et al. (1986), Abdul-Salam and Farah (1988), Daryani et al. (2007), Salih et al. (2011), Kabir et al. (2010). The reason might be associated with keeping of female camel around the house milk purpose and they stay in the backyard where there are infected dogs Parija (2004). While there were a reports recorded that males more susceptible than females as Anwar and Khan (1998).

Hydatidosis in female camel found to be significantly higher than the male animals ( $P < 0.05$ ). Similar findings have been reported by Salih et al. (2011), Abdul-Salam and Farah (1988). Another found that the degree of the infection rate between male and female camel was not statistically significant Ahmadi (2005). Hydatidosis in sheep in regards to sex was not significant ( $P > 0.05$ ).

### The infection rate of Hydatid cyst in slaughtered camels and sheep in relation to age

Hydatid cyst was higher in adult camels and sheep, above two years old (61.25%) and (6.9%) than young animals, below two years old (6.2%)

and (0.15%) respectively. Statistical analysis for hydatid cyst in relation to age was very highly significant in camels ( $P < 0.0001$ ), while there was highly significant differences in sheep ( $P < 0.05$ ). This result was in agreement with Abdel-Hafez et al. (1986), Ibrahim and Craig (1998), Kabir et al. (2010), Yildiz and Gurcan (2003), Senlik (2000), Azlaf and Dakkak (2006). The development of hydatid cyst larva is very slow, and its fertility is only acquired in 12 to 18 months after ingestions of eggs Soule (1994). For these reasons, the inspection of slaughtered young sheep (aged 12 months and under) shows no observable hydatid cyst. Also, this age variation can be again associated with difference in exposure to infection because older livestock may have been exposed to more infective stages Ibrahim et al. (2008).

Older animals may have been exposed to more infective stages and the camel in usual are slaughtered in their old age.

#### **The infection rate of Hydatid cyst in slaughtered camels and sheep in relation to season**

The highest infection of hydatid cyst in camel was found in autumn (10.4%), followed by winter (9.6%), summer (8.5%) and the lowest was noticed in spring (5.4%). Hydatid cyst in sheep was recorded only in autumn (3.41%). There was not significant differences with statistical analysis of camel infected with hydatid cyst in relation to seasonal variation ( $P > 0.05$ ) but in sheep there was significant ( $P < 0.05$ ). This result was in agreement with Kadir and Rasheed (2008), Sameh et al. (2016).

Close contact of camels and sheep with dogs in pastures may help to transmit parasites from infected pasture in autumn and winter were they are rainy and humid seasons. Also, dogs are highly infected by *Echinococcus granulosus* Eslamiand Hosseini (1998).

#### **The infection rate of Hydatid cyst in slaughtered camels and sheep in relation to predilection seats**

The most predilection seats of hydatid cyst in camels were found in the lungs (92.5%), more than liver (4.03%), but in sheep cysts were found in liver (66.67%) more than in lungs (33.33%). While mixed infection of both lungs and liver in camels was (3.47%), but in sheep, mixed infection of both lungs and liver was not found. This result was in agreement with Osman (2013), Moham-

med and El-Malik (2000), Ahmed et al. (2006), Al-Salami et al. (2009), El-Ibrahim (2009), Ibrahim et al. (2011), Magaji et al. (2011), Salem et al. (2011), Fathi et al. (2012), Abo El-Ala (2014). Lung infection with hydatid cyst was statistically very highly significant in association with other predilection seats ( $P < 0.0001$ ). The high number of cysts in the lung may be due to the relatively softer consistency of lung compared to the liver. The lung tissue is more softer in consistency allows the easier development of the cyst than the liver tissue

#### **Fertility of Hydatid cyst among slaughtered camels and sheep**

In this study, the percentages of fertile and infertile hydatid cyst in infected lung of camels were (83.4%) and (16.6%) respectively. While in liver of camel the rate of fertile and infertile cyst was (30%) and (70%) respectively. On the other hand, the fertility of hydatid cyst in infected lung and liver of sheep was (100%). This was in agreement with Dyab et al. (2005), Khalifa et al. (2005), Kassem and Gdoura (2006).

#### **References:**

1. Abdel-Hafez S. K., Al-Yaman F. M., Said I. M. (1986): Further studies on prevalence of hydatidosis in slaughtered animals from North Jordan. *Z. Parasitenkd. J. Vol. 72(1)*, pp. 89–96.
2. Abdul-Salam J. M., Farah M. A. (1988): Hydatidosis in camels in Kuwait. *Parasitol. Res. J. Vol. 74 (3)*, pp. 267–270.
3. Abo El-Ala S. M. E. (2014): Studies on some Metacestodes Infecting Ruminants. M.V.Sc. Thesis of veterinary parasitology, Cairo University.
4. Ahmadi N. A. (2005): Hydatidosis in camels (*Camelus dromedarius*) and their potential role in the epidemiology of *Echinococcus granulosus* in Iran. *Helminthol. J. Vol. 79 (2)*, pp. 119–125.
5. Ahmed S., Nawaz N., Gul R., Zakir M., Abdul Razzaq (2006): Some Epidemiological aspects of hydatidosis of lungs and livers of sheep and goats in Quetta, Pakistan. *Pakistan J. Zool. Vol. 38 (1)*, pp.1–6.
6. Al-Salami O. M., Ali M. Z., Hyderah M. A. (2009): Prevalence of Hydatid cysts in camels in Lahej district --Yemen. *Natural and Applied Sci. J. Vol. 13 (1)*, pp. 33–38.
7. Anwar A. H., Khan M. N. (1998): Parasitic Fauna of Camel in Pakistan. *Proceedings of the Third Annual Meeting for Animal Production under Arid Conditions. Vol. 2*, pp. 69–76.

8. Asma A. L. (2009): Genotyping of *Echinococcus granulosus* in Punjab. PhD. Thesis presented to Department of Zoology, University of the Punjab, New campu, Lahore. pp. 1–119.
9. Bardonnet K., Benchikh-Elfegoun M. C., Bart J. M., Harraga S., Hannache N., Daumon H., Vuitton D. A., Piarroux R. (2003): Cystic echinococcosis in Algeria: cattle act as reservoirs of sheep strain and may contribute to human contamination. *Vet. Parasitol. J.* Vol. 116 (1). pp. 35–44.
10. Daryani A., Alaei R., Arab R., Sharif M., Dehghan M. H., Ziaei H. (2007): The prevalence, intensity and viability of hydatid cysts in slaughtered animals in the Ardabil province of Northwest Iran. *Helminthol. J.* Vol. 81 (1). pp. 13–17.
11. Dyab K. A., Hassanein R., Hussein A. A., Metwally S. E., Gaad H. M. (2005): Hydatidosis among man and animals in Assiut and Aswan Governorates. *Egypt Soc. Parasitol. J.* Vol. 35 (1). pp. 157–166.
12. El-Ibrahim J. H. (2009): Prevalence of Sheep Hydatidosis in North West Bank-Palestine. M.V.Sc. Thesis presented to An-Najah National University, Faculty of Graduate Studies., pp. 1–54.
13. El-Mahdi I. E., Ali Q. M., Magzoub M. M., Ibrahim A. M., Saad M. B., Romig T. (2004): Cystic echinococcosis of livestock and humans in central Sudan. *Ann. Trop. Med. Parasitol. J.* Vol. 98 (5). pp. 473–479.
14. Eslami A., Hosseini S. H. (1998): *Echinococcus granulosus* infection of farm dogs of Iran. *Parasitol. Res. J.* Vol. 84 (3), pp. 205–207.
15. Fathi S., Dehaghi M. M., Radfar M. H. (2012): Occurrence of hydatidosis in camels (*Camelus dromedarius*) and their potential role in the epidemiology of *Echinococcus granulosus* in Kerman area, southeast of Iran. *Comp. Clinic. Pathol. J.* Vol. 21 (5). pp. 921–927.
16. Fikire Z., Tolosa T., Nigussie Z., Macias C., Kebede N. (2012): Prevalence and characterization of hydatidosis in animals slaughtered at Addis Ababa abattoir, Ethiopia. *Parasitol. and Vector Biol. J.* Vol. 4 (1), pp. 1–6.
17. Hamrat K., Achour Y., Bouhousse A., Cozma V. (2011): Study of the prevalence of *Echinococcus granulosus* in the south of Algeria (as in the Adrar region). *Sci. Parasitol. J.* Vol. 12 (4), pp. 219–221.
18. Haridy F. M., Ibrahim B. B., Morsy T. A. (2000): Sheep-dog-man. The risk zoonotic cycle in hydatidosis. *Egypt Soc. Parasitol. J.* Vol. 30 (2), pp. 423–429.
19. Haridy F. M., Ibrahim B. B., Elshazly A. M., Awad S. E., Sultan D. M., El-Sherbini G. T., Morsy T. A. (2006): Hydatidosis *granulosus* in Egyptian slaughtered animals in the years 2000–2005. *Egypt Soc. Parasitol. J.* Vol. 36 (3). pp. 1087–1100.
20. Hassanin F. S., Shaltout F. A. I., Afifi M. E. (2013): Parasitic affections in edible offal. *Benha Vet. Med. J.* Vol. 25 (1). pp. 46–55.
21. Ibrahim M. M., Craig P. S. (1998): Prevalence of cystic *Echinococcus* in camels (*Camelus dromedaries*) in Libya. *Helminthol. J.* Vol. 72. pp. 27–31.
22. Ibrahim M. M. (2010): Study of cystic echinococcosis in slaughtered animals in Al Baha region, Saudi Arabia: Interaction between some biotic and abiotic factors. *ACTA Tropica J.* Vol. 113 (1). pp. 26–33.
23. Ibrahim K., Thomas R., Peter K., Rihab A. O. (2011): A molecular survey on cystic echinococcosis in Sinnar area, Blue Nile state (Sudan). *Chinese Med. J.* Vol. 124 (18), pp. 2829–2833.
24. Ibrahim M. M., Al-Ghamdi M. A., Al-Gahmid M. M. (2008): Helminths community of veterinary importance of livestock in relation to some ecological and biological factors. *Turkiye parazitoloji Dergisi J.* Vol. 32. pp. 42–47.
25. Kabir M. H. B., Eliyas M., AbulHashem M. D., Mohiuddin M., Miazi O. F. (2010): Prevalence of zoonotic parasitic diseases of domestic animals in different abattoir of Comilla and Brahman Baria region in Bangladesh. *Univ. J. Zool. Rajshahi. Univ. Vol.* 28. pp. 21–25.
26. Kadir M., Rasheed S. (2008): Prevalence of some parasitic helminths among slaughtered ruminants in Kirkuk slaughter house, Kirkuk, Iraq. *Iraqi Vet. Sci. J.* Vol. 22 (2). pp. 81–85.
27. Khalifa R. M. A., Abdel-rahman S. M., Monib M., Yones D. A. (2005): Characteristics of Hydatid cyst of camel strain of *Echinococcus granulosus* in Assiut. *El-Minia Med. Bull. J.* Vol. 16 (1). pp. 202–214.
28. Kassem H. H., Gdoura N. K. (2006): Hydatidosis in camels (*Camelus dromedarius*) slaughtered at Sirt Abattoir, Libya. *Egypt Soc. Parasitol. J.* Vol. 36 (2). pp. 1–10.
29. Kassem (2013): Hydatid disease in dromedary camel at Aswan Governorate. PhD. Thesis for Infectious diseases department, Faculty of Veterinary Medicine, Assiut university.
30. Lahmar S., Debbek H., Zhang L. H., McManus D. P., Souissi A., Chelly S., Torgerson P. R. (2004): Transmission dynamics of the *Echinococcus*



- granulosus sheep – dog strain (G1 genotype) in camels in Tunisia. *Vet. Parasitol. J.* Vol. 121 (1–2). pp. 151–156.
31. Lahmar S., Chéhida F. B., Pétavy A. F., Hammou A., Lahmar J., Ghannay A. H., Gharbi A., Sarciron M. E. (2007): Ultrasonographic Screening for Cystic Echinococcosis in Sheep in Tunisia. *Veterinary Parasitology*. Vol. 143. pp. 42–49.
  32. Magaji A. A., Oboegbulem S. I., Daneji A. I., Garba H. S., Salihu M. D., Junaidu A. U., Mohammed A. A., Lawal M., Aminu S., Yakubu Y., Mamuda A. (2011): Incidence of Hydatid cyst disease in food animals slaughtered at Sokoto Central Abattoir, Sokoto State, Nigeria. *Vet. World J.* Vol. 4 (5). pp. 197–200.
  33. Mohamed B. S., Magzoub M. (1989): Hydatidosis in camels and cattle in Sudan. *Sud. J. Vet. Sci. Anim. Husb.* Vol. 28 (1). pp. 27–32.
  34. Mohammed A. A., El-Malik K. H. (2000): The Epidemiology of Cystic Echinococcosis in Nyala, Southern Darfur State, Sudan. *The Sudan Vet. Res. J.* Vol. 16. pp. 49–53.
  35. Muqbil N. A., Al-Salami O. M., Arabh H. A. (2012): Prevalence of unilocular hydatidosis in slaughtered animals in Aden Governorate-Yemen. *Jordan. Biol. Sci. J.* Vol. 5 (2). pp. 121–124.
  36. Osman A. M. A. (2013): Pathological and Biomolecular Study on Hydatid Disease in Camels, Cattle and Sheep. University of Khartoum, M.V.Sc. Thesis and dissertation.
  37. Parija S. C. (2004): Medical Parasitology, Protozoology and Helminthology text and Atlas. 2nd Ed. India chennia medical Books Publisher. pp. 221–229.
  38. Pednekar R. P., Gatne M. L., Thompson R. C., Traub R. J. (2009): Molecular and morphological characterization of Echinococcus from food producing animals in India. *Vet. Parasitol. J.* Vol. 165 (1–2). pp. 58–65.
  39. Rokni M. B. (2009): Echinococcosis / hydatidosis in Iran. *Iran. J. Parasitol.* Vol. 4 (2). pp. 1–16.
  40. Saeed I., Kapel C., Sel-Massry L. A., Willingham L., Nansen P. (2000): Epidemiology of Echinococcus granulosus in Arbil province, Northern Iraq, 1990–1998. *Helminthol. J.* Vol. 74 (1). pp. 83–88.
  41. Salem C. B. O. A., Schneegans F., Chollet J. Y., Jemli M. H. (2011): Epidemiological Studies on Echinococcosis and Characterization of Human and Livestock Hydatid Cysts in Mauritania. *Iran. J. Parasitol.* Vol. 6 (1). pp. 49–57.
  42. Salih M., Degefu H., Yohannes M. (2011): Infection Rates, Cyst Fertility and Larval Viability of Hydatid Disease in Camels (*Camelus dromedarius*) from Borena, Kereyu and Harar Areas of Ethiopia. *Global Veterinaria J.* Vol. 7 (6). pp. 518–522.
  43. Same B., Baker M., Sarouk B. (2016): Anatomopathology study of Echinococcosis in slaughtered sheep in the region of Batna (East Algeria). *Imp. Interdisciplinary Res. J.* Vol. 2(3). pp. 552–556.
  44. Seimenis A. (2003): Overview of the epidemiological situation on echinococcosis in the Mediterranean region. *Acta. Trop. J.* Vol. 85(2). pp. 191–195.
  45. Senlik B. (2008): Influence of Host Breed, Sex, and Age on the prevalence an intensity of *Cysticercus tenuicollis* in sheep. *Turkey J. of Animal and Vet. Advanceca.* Vol. 7 (5). pp. 548–551.
  46. Soule C. (1994): The hydatid disease of ruminants. *Veterinary Point. Maisond'Alfort. France.* 26 (special number). pp. 930–933.
  47. Smyth J. D. (1967): Studies on tapeworm physiology. XI. In vitro cultivation of *Echinococcus granulosus* from protoscolex to the strobilate stage. *Parasitology.* Vol. 57. pp. 111–133.
  48. Toulah F. H., Amal A. E., Muslimah N. (2012): Prevalence of hydatidosis among slaughtered animals in Jeddah, Kingdom of Saudi Arabia. *Egypt Soc. Parasitol. J.* Vol. 42 (3). pp. 563–572.
  49. Yang Y. R., Rosenzvit M. C., Zhang L. H., Zhang J. Z., McManus D. P. (2005): Molecular Study of Echinococcus in West-Central China. *Parasitology J.* Vol.131. pp. 547–555.
  50. Yildiz K., Gurcan S. (2003): Prevalence of hydatidosis and fertility of hydatid cysts in sheep in Kirikkale, Turkey. *Acta Veterinaria Hungarica J.* Vol. 51 (2). pp. 181–187.